

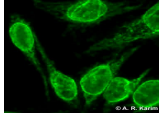
Nuclear without mitotic staining

As mentioned earlier, pattern recognition is based on examining the binding of auto-antibodies to Human epithelial type 2 (HEp-2) cells at the interphase and the dividing stages (metaphase) of the cells. The combination of the reactions seen at these stages defines the pattern. The react of the antinuclear antibodies presented here is confined to interphase only and no reaction is seen in metaphase.

ANA: Nuclear rim (membranous)

[Open all sections](#)

HEp2 cells



Much finer rim than the above. Homogenous staining of the nuclear membrane forming a rim pattern. Folding of the membrane is characteristic of this pattern.

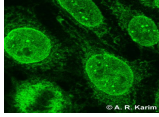
Antigen: Lamins A, B1, B2, C

Clinical: Mixed chronic disorders, chronic fatigue syndrome

[\(/Images/College-MDS-only/facilities/cis/cis-image-library/images/Hep20224705.jpg\)](#)

ANA: Nuclear membrane pores

HEp2 cells



Nuclear membrane surface dots when adjusting fine focus.

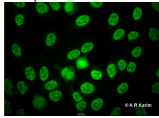
Antigen: gp210, nucleoporin p62

Clinical: PBC and polymyositis

[\(/Images/College-MDS-only/facilities/cis/cis-image-library/images/HEP2pores.jpg\)](#)

ANA: Nuclear Matrix

HEp2 cells



Large, variable size, speckles arranged in sponge-like pattern (often referred to as "crazy paving")

Antigen: Heterogenous ribonuclear proteins (hnRNP)

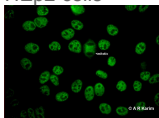
Clinical: SLE, mixed connective tissue disease, rheumatoid arthritis & scleroderma

[\(/Images/College-MDS-only/facilities/cis/cis-image-library/images/nmxh0445902.jpg\)](#)

ANA: Coarse speckled

Dense intermediate sized speckling of the nucleus.

HEp2 cells



Antigens

Sm
U1-snRNP U2-snRNP
U4/U6-snRNP

Clinical

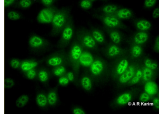
SLE (5-30%)
SLE (15-40%), SLE, MCTD (95-100%)
SLE, MCTD, Raynaud's phenomenon, Psoriasis, Sjögren's syndrome and systemic sclerosis

[\(/Images/College-MDS-only/facilities/cis/cis-image-library/images/csp0532996.jpg\)](#)

ANA: Fine speckled

Fine granular (uniform) staining of the HEp-2 nucleus.

HEp2 Cells



Antigens

Mi-2
SSA/Ro, SSB/La,
RNA polymerase II

Clinical

Dermatomyositis
Sjögren's syndrome, SLE, congenital heart block
Systemic Sclerosis

[\(/Images/College-](#)

[MDS-](#)

[only/facilities/cis/cis-](#)

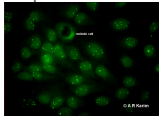
[image-](#)

[library/images/fsp0532992.jpg\)](#)

ANA: Few nuclear dots

Up to six dots in the nuclei.

HEp2 Cells



Antigens

Mi-2
p80 coilin

Clinical

Primary biliary cirrhosis (30%),
chronic active hepatitis

[\(/Images/College-](#)

[MDS-](#)

[only/facilities/cis/cis-](#)

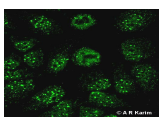
[image-](#)

[library/images/dsp0447236.jpg\)](#)

ANA: Multiple nuclear dots

Between 6 and 10 dots in the nuclei of the HEp-2 cells.

HEp2 Cells



Antigens

Sp 100

Clinical

Primary biliary cirrhosis (6%),
Sjögren's syndrome, SLE

[\(/Images/College-](#)

[MDS-](#)

[only/facilities/cis/cis-](#)

[image-](#)

[library/images/Multiplenucleardots.jpg\)](#)

MCTD = Mixed Connective Tissue Disease

[Privacy](#) | [Legal](#) | [Cookies and cookie policy](#) | [Accessibility](#) | [Site map](#) | [Website feedback](#) | [Charitable information](#)

© University of Birmingham 2015

