We use cookies to ensure that we deliver the best user experience of our website. If you would like to, you can change your cookie settings at any time. Continue

Neurological Cases

In order to complement the autoimmune neurology we have added few clinical cases associated with the autoantibodies shown on this site. Below are few examples which we wish to share with the vistors to this site.

Open all sections

Metastatic adenocarcinoma

Patient history

- 71 years old female
- Pancerebellar dysfunction with 2-stone weight loss over 2 months
- Normal cerebellar MRI
- CT scan identified para-aortic lymphadenopathy metastatic adenocarcinoma of unknown origin

Biochemical parameters

- Normal CSF lymphocyte count, protein and glucose levels
- **Oligoclonal bands (/facilities/clinical-immunology-services/neuroimmunology/other-services/OCB-patterns.aspx)** present in the CSF only
- Elevated serum CA-125 to 312KU/L
- IgG antibodies to HEp2, myenteric plexus, cerebellum and patient tumour show staining of the cytoplasm
- The distribution of the staining was similar to that of Yo antibody. Serum and CSF anti-neuronal antibody titre was 1:8000 and 1:100 respectively
- The antibody recognised a 22.5 KDa band on Western blot of the prmate cerebellum extract

The images below show the reaction of patient sera with cerebellum, peripheral nerve, HEp2 and patient tumour:

Cerebellum

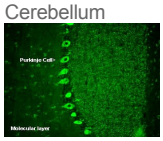

(/Images/College-MDS-only/facilities/cis/neuroimmunology/dof(1).jpg)

Peripheral nerve

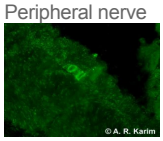

(/Images/College-MDS-only/facilities/cis/neuroimmunology/dof(2).jpg)

HEp2 Cells

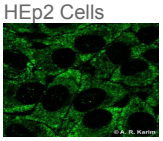

(/Images/College-MDS-only/facilities/cis/neuroimmunology/dof(3).jpg)

Patients tumour

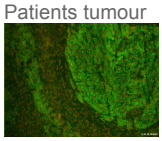

(/Images/College-MDS-only/facilities/cis/neuroimmunology/dof(7).jpg)

(Karim, Stubbs, Bradwell and Williams; J Neuroimmunology (2001), 118:156 (No. 484))

Mesothelioma

Patient history

- 62 year old male with history of right-sided pleural effusion
- Smoked 20/day then switched to smoking pipe daily
- Biopsies confirmed diagnosis of mesothelioma

During the following two years:-

- He complained about double vision

Neurological examination

- Broad-based ataxic gait veering to both sides
- Some nystagmus on lateral gaze
- Muscle wasting, no weakness or pins and needles
- MRI normal
- Some double vision
- One year later, patient died

Immunological data

Patient sera reacted with cerebellum producing a typical pattern that was Identified as Ma antibody. Both Ma1 and Ma2 were detected (see paraneoplastic neurological antibodies for typical pattern).

Post-mortem

- **Tumour metastasised to lymph node with mediastinum, chest wall, right adrenal gland and liver**

Most common Ma1 syndromes: brain-stem encephalitis, cerebellar degeneration
Associated tumours: Lung and other cancers

Most common Ma2 syndromes: limbic brain-stem encephalitis
Associated tumours: testicular cancers

Hodgkin's disease

Patient history

- 63 year old male with Nodular Sclerosing Hodgkin's disease
- Received six cycles of chemotherapy (adriamycin, bleomycin, vinblastine, and dacarbazine, (ABVD)) and responded well.
- CT scan showed complete remission from Hodgkin's disease.
- Shortly after treatment complained of balance problem

Neurological examination

- Slurred speech
- Walked with broad based gait and small steps
- Finger, nose and heel shin ataxia worse on the left side with normal power
- Slight nystagmus to the right
- MRI showed a lesion consistent with ischaemic events and compression of L1 and T11 (due an previous accident)
- He was diagnosed as having cerebellar syndrome of unknown origin

Immunological data

Patient sera reacted with cerebellum and the pattern identified was that of **Tr antibody** (see paraneoplastic neurological antibodies for typical pattern).

Neuronal antigen: no common band identified on Western blot Identification is based on immunocytochemical distribution alone
.

Tr syndromes: Cerebellar degeneration
Associated tumours: Hodgkins disease

Primary biliary cirrhosis/sclerosing cholangitis

Patient history

- 71 year old female
- 20 cigarettes a day
- 10-20 units of alcohol/week
- Diagnosed as having primary biliary cirrhosis/sclerosing cholangitis and Irritable bowel syndrome

Neurological examination

- Diarrhoea, vomiting and gradual weight loss
- Developed numbness, pain, pins & needles in left foot and leg. Later spread to both hands
- Wide unsteady gait
- Bilateral finger/nose ataxia
- Limbic encephalitis with focal seizures and choreiform movements
- Brain CT scan normal
- No underlying malignancy found

Immunological data

- Negative lupus anticoagulant test, ANA, ENA and ANCA
- Negative for ganglioside & Voltage Gated Calcium Channel
- IgM raised to 4.25g/l together with anti-mitochondrial antibody titre >100 AU/ml
- High titre of anti-mitochondrial antibody masked any other reactions on the cerebellum at all dilutions. Underlying paraneoplastic **anti-Hu** antibody was revealed with a Western blot (see the example under other antibodies and also paraneoplastic neurological antibodies for typical pattern).

Outcome:

- Five years later there was progressive neurological deterioration of neurological function
- Sensory neuropathy
- Focal seizures
- No occult malignancy found

© University of Birmingham 2014